

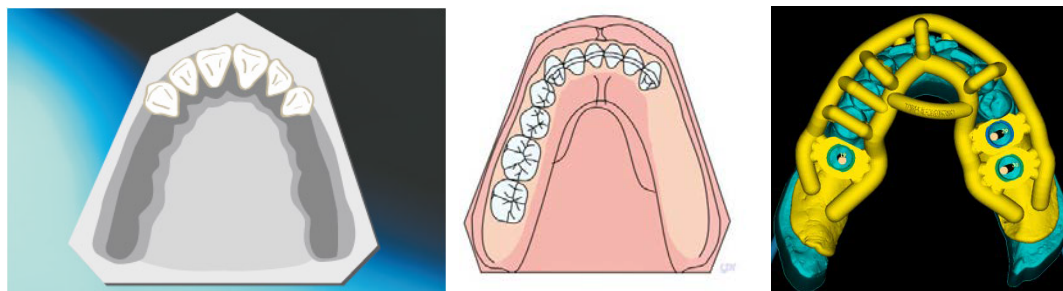
MGUIDE Tips and Tricks: Free End Cases (Partially Edentulous, Kennedy Class I and Class II)

CT scan:

- 1) Ensure that you are using a CT scanner that does not stitch the image (a stitched image is one with more than one image combined to form a whole)
- 2) The thickness of each CT slice should not exceed 0.2 mm for mandibular cases and 0.3 mm for maxillary cases
- 3) Ensure that the patient keeps an open bite (there should be no contact between upper and lower teeth)
- 4) The patient's tongue must not rest on the gums of the arch being scanned
 - Maxillary Cases: Tongue must rest on the floor of the mouth
 - Mandibular Cases: Tongue must rest up and back against the posterior vibrating line of the mouth
- 5) Make sure the entire arch is visible, including the incisal edges of all teeth on that arch
 - Maxillary Cases: The scan must show the entire arch and at least 50% of the sinuses
 - Mandibular Cases: The scan must show the entire arch and the mandibular nerve
- 6) Remove any type of partial denture (flipper) if the patient is wearing one
- 7) If there are edentulous areas prior to surgery, place cotton rolls in the vestibule of the mouth during scanning

Impressions:

- 1) **Do not** use Alginate impression material
- 2) Vinyl Polysiloxane or similar materials are recommended
- 3) **Use a custom tray** to take the impressions and make sure the gums are captured accurately. The surgical guide will depend heavily on mucosal support for stability as shown in the below figures
- 4) Do not pour the impressions, send them to the MCENTER and they will be poured there.
- 5) Digital impressions are accepted. Call the **MCENTER** for details 844-220-3458



Left: Bilateral upper free-end case. Middle: Lower free-end case. Right: Surgical guide on a lower bilateral free-end case.